

2014 OPEN FORUM

Presented by

Supported by an unrestricted educational grant
from

RESPIRATORY CARE monaghan™

The OPEN FORUM at the AARC Congress 2014 is an unique opportunity for attendees to experience the results of scientific studies performed by their colleagues. RESPIRATORY CARE is proud to present this year's OPEN FORUM. Once again, respiratory care professionals have stepped forward and analyzed the things they do with critical eyes. For the first time ever, this year posters will be presented in one of 3 formats:

Editors' Choice – The top 6 abstracts in 2014. On the first two days of the Congress the Editors' Choice posters will be displayed by the entrance to the Exhibit Hall. On the third day, each presenter will discuss their findings in a 10-minute slide presentation, which will be followed by a 10-minute question and answer period.

Poster Discussions – Sixteen sessions, grouped by topics, will be presented over the four days of the Congress. During the first part of the session attendees will be able to review the posters and discuss them with the authors. In the second part presenters will expand on the work shown on the poster with a brief oral presentation (no slides).

Posters Only – Posters will be displayed inside the Exhibit Hall during the three days of exhibits. Different categories each day. Authors will be present for questions and answers from 12:00 pm to 1:30 pm.

OPEN FORUM Sessions

Tuesday, December 9

| | |
|---|---|
| Posters Only #1 11:30 am – 3:30 am | Neonatal/Pediatric Ventilation/Ventilators |
| Poster Discussions #1 3:15 pm – 5:10 pm | Aerosols/Drugs – Part 1 |
| Poster Discussions #2 3:15 pm – 5:10 pm | Monitoring/Equipment – Part 1 |

Wednesday, December 10

| | |
|---|--|
| Poster Discussions #3 10:00 am – 11:55 am | Ventilation/Ventilators – Part 1 |
| Poster Discussions #4 10:00 am – 11:55 am | Diagnostics |
| Posters Only #2 10:30 am – 2:30 pm | Aerosols/Drugs Asthma/Pulmonary Disease Case Reports Home Care Sleep/Pulmonary Rehab O ₂ Therapy |
| Poster Discussions #5 12:30 pm – 2:25 pm | Neonatal/Pediatric – Part 1 |
| Poster Discussions #6 12:30 pm – 2:25 pm | Education – Part 1 |
| Poster Discussions #7 3:10 pm – 5:05 pm | Asthma/Pulmonary Diseases |
| Poster Discussions #8 3:10 pm – 5:05 pm | Home Care/O ₂ Therapy |

Thursday, December 11

| | |
|---|--|
| Poster Discussions #9 9:30 am – 11:25 am | Aerosols/Drugs – Part 2 |
| Poster Discussions #10 9:30 am – 11:25 am | Management |
| Editors' Choice 9:30 am – 11:55 am | Top 6 abstracts in 2014 |
| Posters Only #3 10:30 am – 2:30 pm | Airways Care Diagnostics Education Management Monitoring/Equipment |
| Poster Discussions #11 12:30 pm – 2:25 pm | Airways Care |
| Poster Discussions #12 12:30 pm – 2:25 pm | Ventilation/Ventilators – Part 2 |
| Poster Discussions #13 3:15 pm – 5:10 pm | Case Reports |
| Poster Discussions #14 3:15 pm – 5:10 pm | Education – Part 2 |

Friday, December 12

| | |
|---|-------------------------------|
| Poster Discussions #15 9:00 am – 10:55 am | Neonatal/Pediatric – Part 2 |
| Poster Discussions #16 9:00 am – 10:55 am | Monitoring/Equipment – Part 2 |

See pages OF83-OF89 for OPEN FORUM Author Index

The Journal and the OPEN FORUM organizers are not responsible for any injury and/or damage to persons or property as a matter of products liability, negligence or otherwise, or from any use or operation of any methods, products, instructions or ideas contained in the abstracts published here. Advances in the medical sciences occur every day and we strongly recommend independent verification of treatment modalities, diagnoses and drug usages.

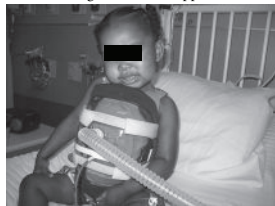2006727

CASE REPORT FOR CHEST CUIRASS IN TODDLER WITH DIAPHRAGM WEAKNESS POST HEART TRANSPLANT.

Ginger Weid^{1,3}, Justin Young^{1,3}, Shriprasad R. Deshpande^{2,3}; ¹RCP, Children's Healthcare of Atlanta, Atlanta, GA; ²Emory University, Atlanta, GA; ³Sibley Heart Center, Children's Healthcare of Atlanta, Atlanta, GA

Introduction: Diaphragm weakness/paralysis can occur in patients using the Berlin Heart. The Berlin heart is used to assist the heart in maintaining adequate cardiac output or if it cannot adequately provide oxygenated blood to vital organs. The insertion of the device requires the cannulas to be placed through the diaphragms to get to the heart which can lead to diaphragm weakness/paralysis after removal. It is intended to provide cardiac support to the heart for patients awaiting heart transplant. Biphase Cuirass Ventilation (BCV) is the ideal mode of ventilation for patients suffering muscle weakness. It is a noninvasive way to actively control both phases of the respiratory cycle. It can actually improve and redevelop the respiratory muscles weakened due to respiratory failure. IRB determination was that this case was not research and therefore not subject to IRB review. **Case Summary:** The patient was a 2 year old with a complex history that began with viral myocarditis. The patient underwent VA ECMO and was placed on a Berlin heart until time of heart transplant. The patient suffered from diaphragm weakness due to previous Berlin heart placement. The patient had several admissions for recurring pneumonia and chronic hypercarbia that required multiple intubations. It was decided to place the child on Biphase Cuirass Ventilation via the Hayek RTX Ventilator prior to extubation. The initial settings were control mode rate of 20, -12/+3 while sleeping and CNEP-8 cm while awake. The patient received CPAP with Pressure Support via conventional ventilator. After several hours and comfort achieved on the Chest Cuirass the patient was extubated. The secretion clearance mode was also used on this patient to help generate a cough and maintain lung clearance. The patient remained on the chest cuirass for several months as an inpatient. During this time the patient transitioned to up to 4 hours a day off the device and discharged home on 14, -14/+3 settings. **Discussion:** Biphase Cuirass Ventilation (BCV) can be a lower cost and noninvasive alternative to tracheostomy for some patients. Compared to other types of noninvasive ventilators BCV is easily fitted to small children and does not require sedation. More information and education is needed concerning the availability of the device as an alternative to tracheostomy in some patients. **Disclosures:** Conference support pending from Hayek Medical Devices.

Sponsored Research - Hayek is considering conference support



2011010

A CASE SERIES OF FOUR TECHNOLOGY DEPENDENT INFANTS WITH COMPLICATIONS DURING NEBULIZER THERAPY.

Shannon Short, Cynthia White, Rick Ehlman, Neepa Gurbani; Cincinnati Children's Hospital Medical Center, Cincinnati, OH

Introduction: Adding flow into neonatal and pediatric ventilator circuits during nebulizer therapy has always been a concern in this population. Previous bench and clinical evaluations have identified complications with both patient ventilator synchrony and impact on ventilator parameters when additional flow is added into the circuitry. Recent advances in technology such as vibrating mesh nebulizers (VMN) have eliminated or reduced the need to add additional flow into ventilator circuits during nebulizer therapy. These technologies have not yet entered the home care market secondary to barriers related to access, expense, and reimbursement. In this case series, we are reporting the incidence of four infants with chronic lung disease (CLD) who all developed respiratory distress while receiving SVN's in line with sub acute ventilators. **Case Series:** All four patients in this case series were being ventilated in pressure ventilation on a Trilogy ventilator (Phillips Respironics, Carlsbad, CA) with a 22 mm passive circuit and a disposable exhalation valve. Sensitivity on three of the patients was set on a flow trigger or 1 and the fourth was set on autotrak (sensitive). Each patient was less than twelve months of age and weighed less than 10 kg. Immediately after the start of nebulizer therapy, all four infants developed increased work of breathing, retractions, and desaturation. All of the treatments were administered by an AirLife@MistyFinity@Nebulizer SVN (Carefusion, Yorba Linda, CA) that was powered by the Respironics Inspiration compressor (Phillips Respironics, Carlsbad, CA). **Discussion:** The above case series reveals that ventilator dependent infants under 10kg with CLD may be at risk for developing respiratory distress during nebulizer therapy with via a standard SVN. Patients in the homecare setting are at higher risk secondary to having limited control over the L flow with a compressor to power the SVN. Screening ventilator dependent infants prior to discharge or in pulmonary clinic setting may be necessary to assess the need to switch patients at risk to MDI's or alternative therapies.

Sponsored Research - None

2007192

ECMO AND HIGH FREQUENCY JET VENTILATION FOR NECROTIZING PNEUMONIA COMPLICATED BY BRONCHOPLEURAL FISTULA IN A PEDIATRIC PATIENT

Gary R. Lowe¹, Randy Willis¹, Mark Heulitt^{1,2}; ¹Respiratory Care, Arkansas Children's Hospital, Little Rock, AR; ²Department of Pediatrics, Critical Care Medicine Section, University of Arkansas for Medical Sciences, Little Rock, AR

Introduction: Severe and rapid decompensation can occur in patients presenting with necrotizing pneumonia caused by methicillin sensitive *Staphylococcus aureus* (MSSA). This case illustrates the course of a previously healthy 6 week old female with MSSA and strategies implemented for her recovery. **Case Summary:** This infant presented to an outside hospital after being found minimally responsive by her parents. The patient was intubated for respiratory failure, placed on conventional ventilation (CV), and transferred to our center. Chest x-ray (CXR) revealed complete right lung consolidation and tension pneumothorax. A chest tube was placed. Pleural fluid and a bronchioalveolar lavage (BAL) were obtained, cultured, and found positive for MSSA. Serial CXR noted pneumatoceles in the right lung, and development of a bronchopleural fistula (BPF) while on CV. On day 2, respiratory status deteriorated requiring VA-ECMO. Lung protective strategy utilizing PEEP (15 cmH₂O) and left mainstem intubation was performed to allow resolution of the BPF. She was transitioned to High Frequency Jet Ventilation (HFJV) to improve lung recruitment and minimize air leak. On day 3, the ETT was pulled back to allow for recruitment of the right lung. Despite HFJV, she continued with significant air leak, but remained stable on VA-ECMO. On day 11 she transitioned to CV without incident. On day 15, chest CT showed fluid surrounding the right lung and necrotic areas within both lungs. ECMO was successfully discontinued on day 17. After transition to CV in PRVC mode, BPF reoccurred. On day 23, her respiratory status declined and nitric oxide (iNO) was started. On day 25, she improved by being placed prone. iNO was weaned and prone positioning was continued. iNO was discontinued on day 29. Her respiratory status improved and on day 32 she transitioned to volume support, with successful extubation on day 35 to 8 LPM high flow nasal cannula (HFNC) at 100% F_iO₂. The chest tube was removed on hospital day 36. HFNC was discontinued on day 48 with hospital discharge on day 65. **Discussion:** Necrotizing pneumonia caused by MSSA can be lethal in the pediatric population. This case illustrates three important points: 1) Infection with MSSA can cause rapid deterioration in respiratory status requiring ECMO, 2) HFJV can aid in lung recruitment and potentially minimize persistent air leak caused by BPF, and 3) Other strategies including iNO and prone positioning can facilitate ventilatory improvement.

Sponsored Research - None

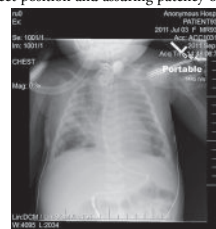2013907

INDEPENDENT LUNG VENTILATION UTILIZING HIGH FREQUENCY JET VENTILATION IN A TWO MONTH OLD WITH CONGENITAL PULMONARY AIRWAY MALFORMATION.

Ryan P. Sura, Bill Wheeler; Children's Hospitals and Clinics of Minnesota, Minneapolis, MN

Introduction: Independent lung ventilation (ILV) is a strategy used for patients with non-homogenous lung disease. This is a 2 month old female ventilated with ILV and HFJV that was being considered for lung transplant. **Case Summary:** A term infant presented with tachypnea, hypoxia, and persistent left lower lobe atelectasis. CT scan showed Left CPAM and grossly abnormal lung development. CPAM was surgically removed on day 10 of life. Post-op she required HFOV due to high ventilating pressures and respiratory acidosis. A tracheostomy tube was placed at one month of age. Throughout her NICU course, she continued to have: persistent left lung atelectasis, persistent extreme hyperinflation of the right lung, and severe respiratory acidosis. Her PaCO₂ ranged from 45-130mmHg throughout the next month. The decision was made to trial ILV and ventilate her right lung via HFJV. To initiate this we made the following interventions: fiberoptically intubated her left bronchus through her tracheostomy stoma with a 3.5 cuffed ETT, orally intubated her trachea with a 3.0 ETT to ventilate her right lung. The left lung was ventilated via conventional ventilation (PC/AC Rate 40 PIP 40 PEEP 3 Ti 0.35 F_iO₂ 100%) to achieve 4 ml/kg Vte. The right lung was ventilated with HFJV via the oral tube. Initial HFJV settings were: PIP25 Rate420 Ti.02s; the CMV was set at Rate2 PIP18 PEEP5 Ti.035 F_iO₂ 100%. ABG prior to initiation was: pH 7.32/PaCO₂ 102/PaO₂ 171/HCO₃ 53. ABG 2 hours after initiation: pH 7.47/PaCO₂ 72/PaO₂ 62/HCO₃ 48. CXR three hours after initiation showed markedly improved aeration of left lung and markedly reduced hyperinflation of the right lung. This strategy continued for two days uneventfully with PaCO₂ 67-80 and pH 7.30-7.45. On day three, transient respiratory acidosis developed due to left lung ETT leak. On day 5 ILV was aborted and conventional ventilation was initiated through her tracheostomy tube to facilitate better secretion clearance and prepare for transport. **Discussion:** Initiating ILV in an infant can be logistically difficult, but the presence of a tracheostomy can be beneficial. Our greatest challenge during this process was maintaining the airways in correct position and assuring patency of each. **Disclosures:** none.

Sponsored Research - None



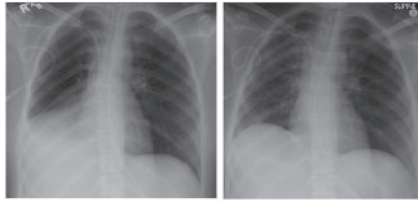
3 hours after initiating ILV+HFJV. Left sided endobronchial tube. Oral endotracheal tube. Markedly decreased hyperinflation of right lung. Markedly increased aeration of left lung.

2016232

NOVEL USE OF FIBEROPTIC BRONCHOSCOPY TO TREAT PERSISTENT LOBAR CONSOLIDATION.

L.K. Jacques¹, Robert DiBlasi¹, Edward Carter²; ¹Pulmonary Diagnostics, Seattle Childrens, Seattle, WA; ²Division of Pulmonary and Sleep Medicine, Banner Children's Specialists, Banner Health, Mesa, AZ

INTRODUCTION: We describe an innovative therapeutic intervention using equipment and personnel available in most children's hospitals to manage persistent lobar collapse. **CASE REPORT:** A 14 year-old female with acute lymphocytic leukemia status post bone marrow transplant was transferred to the PICU for management of multi-organ (hepatic, renal, cardiac, respiratory) failure. She was intubated and placed on high frequency oscillatory ventilation due to poor lung compliance and refractory hypoxemia. The patient's condition improved over the next nine days, enabling transition to conventional mechanical ventilation. As she clinically improved she was noted to have a persistent right lower lobe (RLL) consolidation. Initial fiberoptic bronchoscopy revealed tenacious secretions in the RLL bronchus, which could not be suctioned through the bronchoscope's narrow channel. When no improvement was noted two days after the initial bronchoscopy, the Attending Pulmonologist used a 2.2 OD fiberoptic bronchoscope as a styler to guide a 12 French suction catheter into the RLL bronchus. The internal diameter of this catheter is 2.25 times greater than that of the suction channel of the 3.8mm OD pediatric bronchoscope used in the first procedure. The suction catheter was cut at the proximal end so that it could slip over the bronchoscope. Special attention was paid to lubrication to facilitate removal of the scope from the suction catheter once proper position in the RLL bronchus was achieved. The bronchoscope/suction catheter was then inserted into the 6.0 endotracheal tube and advanced into the RLL. Once the bronchoscope was removed, with the suction catheter remaining in place, 40 ml of 0.9% saline was instilled through the catheter, and then a large amount of thick, purulent secretions was suctioned out. The patient tolerated this well. The initial post-procedure CXR showed some improvement, and two days after the second procedure there was markedly improved aeration of the RLL. Four days after the procedure, the patient was successfully extubated. **DISCUSSION:** It is feasible to use a small flexible bronchoscope to safely guide a large 12 French suction catheter into a bronchus to facilitate removal of thick secretions from the airways. Sponsored Research - None



Pre Intervention x-ray Post Intervention x-ray

2021213

THE VENTILATOR MANAGEMENT OF A CONGENITAL DIAPHRAGMATIC HERNIA IN A NEONATE: A CASE REPORT.

Stephanie A. Bailes¹, Teresa A. Volko², Harriet J. Feick³; ¹Respiratory Care, Akron Childrens Hospital, Akron, OH; ²Nursing Administration, Akron Childrens Hospital, Akron, OH; ³Neonatology, Akron Childrens Hospital, Akron, OH

INTRODUCTION: Patients diagnosed with congenital diaphragmatic hernia require ventilatory assistance before and after surgical repair secondary to respiratory distress, pulmonary hypertension and pulmonary hypoplasia. We present a case of a diaphragmatic hernia in which NAVA was used to facilitate liberation after surgical repair of a diaphragmatic hernia with a complicated medical course. **CASE REPORT:** A term male infant born by caesarian section with an in utero diagnosis of congenital diaphragmatic hernia had Appgars of 4 and 7. Delivery room resuscitation included intubation, mechanical ventilation, fluid resuscitation, and temperature regulation. Pulmonary hypertension, confirmed by echocardiogram, was treated with paralytics, sedation, pressure control ventilation and inhaled nitric oxide for 8 days. Diaphragmatic surgical repair was performed on day of life (DOL) 9. The postoperative course was complicated by pneumo-pericardium/mediastinum and recurrent pleural effusions requiring bilateral chest tubes, extracorporeal membrane oxygenation and high frequency oscillation ventilation with nitric oxide titration for lung recovery. On DOL 18, the patient transitioned to pressure control ventilation with an inspiratory pressure 22 H₂O, f 48/minute, T_i

2016799

THE IMPACT OF AIRWAY RESISTANCE ON VENTILATOR ALARMS IN PEDIATRIC PATIENTS.

Christy Dyer¹, Neepa Gurbani², Cynthia White¹; ¹Respiratory Care, Cincinnati Children's Hospital Medical Center, Cincinnati, OH; ²Division of Pulmonary Medicine, Cincinnati Children's Hospital Medical Center, Cincinnati, OH

Background: To improve patient safety, JCAHO issued a National Patient Safety Goal (NPSG) focused on alarm management. Expectations will be for organizations to improve their systems by finding a balance between prioritizing safety alarms, and preventing nuisance alarms that may result in alarm fatigue. Disconnect alarms on mechanical ventilators are an example of a high priority alarm that needs to occur to ensure patient safety. Alarm settings are impacted by patient size, ventilator settings, operational features of each vent type, and circuit configuration type (active vs. passive). The following case series highlights complications with occurrence of a circuit disconnect alarm when a size infant ETCO₂ adapter was added to the ventilator circuit configuration. **Case Series:** Both patients in this case series were patients in our Transitional Care Center (TCC), who required long term ventilator support using a Trilogy 202 (Phillips Respironics, Carlsbad, CA) ventilator with a passive circuit in SIMV PC mode. Both were under the age of 6 m/o, weighed < 10kg, and had Neo Extend Connect tracheostomy tubes (Smith Medical, Dublin OH). Patient #1 had a size 3.5 x 34. Patient #2 had a 3.0 x 32. Both patients did not have a circuit disconnect alarm occur with the purple size Ped/Infant ETCO₂ monitor (Phillips Respironics, Carlsbad, CA) in line with vent circuit. When the purple adapter was removed, the alarm occurred reliably. Both patients had low minute ventilation alarms occur within 10 seconds as long as the low minute ventilation alarm was set within a high enough percent of tidal volume. We discovered we were able to place a clear Adult/Ped ETCO₂ monitor in line while getting the disconnect alarm with more consistency. An NM3 monitor was placed in line to compare the impact of changes in ventilation with each of these adapters compared to no adapter. See attached graph for data comparison. WOB was not impacted with either of the ETCO₂ adapters. **Discussion:** Chronic pediatric patients have historically been ventilated in pressure ventilation with low minute ventilation being the only reliable ventilator disconnect alarm. The addition of specific disconnect alarms are valuable safety features for home ventilators. This case series highlights the need to consider the impact of additional monitors that may be added to the vent circuit when designing disconnect alarms. The concept of timed versus average alarms may also be worthwhile for patients with leaks. Sponsored Research - None

2022018

THE UNIQUE APPLICATION OF NEGATIVE PRESSURE CUIRASS VENTILATION IN A PEDIATRIC PATIENT.

Mark A. Washam^{1,3}, Laura Burke², Cynthia White², Neepa Gurbani¹, Hemant Sawhani¹; ¹Division of Pulmonary Medicine, Cincinnati Childrens Hospital Medical Center, Cincinnati, OH; ²Respiratory Care Department, Cincinnati Childrens Hospital Medical Center, Cincinnati, OH; ³Analytical and Diagnostics Sciences - Respiratory Therapy, University of Cincinnati, Cincinnati, OH

Abstract Body: Until the mid-1950s, negative-pressure ventilation (NPV) was commonly used in patients requiring mechanical ventilation. Currently, NPV is enjoying resurgence in use in many patient populations utilizing the cuirass (clam shell device over the chest, upper abdomen). We describe the unique application of NPV, Biphasic Cuirass Ventilation (BCV, United Hayek, United Kingdom), in a 3 year old boy with paraplegia from spinal cord injury at thoracic vertebra T3 to cervical vertebra C5. BCV is a unique mode of NPV most significantly using an active expiratory cycle and varying modes/sensitivities. **Case Summary:** The child had a tracheostomy since 1 year of age, and was actively weaned from the ventilator. However, he had a chronic history of insomnia and restlessness in sleep. He had need for frequent pulmonary toilet for secretion management. He was admitted and managed for respiratory distress, hypoxemia, pneumonia and chronic atelectasis. He was managed with Positive Pressure Ventilation (PPV), aggressive and frequent airway clearance, mucolytics and frequent bronchoscopy. Atelectasis was recurrent and persistent with notable mucus plugging. Clinically, this patient was observed to have marked mid thoracic dyssynchrony, in that his superior thorax was still supported by neck muscles, but his lower appeared to be a flail chest due to his lower cervical spine injury. BCV was initiated in an effort to improve his pulmonary toilet. Initial settings: Ipress -24, Epress +3 and a rate of 20. He was easily ventilated and oxygenated at these settings, and there was rapid, complete radiographic clearing of atelectasis. The patient tolerated BCV well and over time was allowed to window off PPV and BCV for 30 minutes with a speaking valve. His windows off support and on his speaking valve were gradually extended to a maximum of 2-3 hours a few times daily. **Discussion:** BCV use proved successful in maintaining adequate ventilation and, secretion clearance, with resolution of atelectasis in this patient with paraplegia and a lower cervical spinal cord injury. It was easily applied, well tolerated, and free of complications. Technical complications with the device and inadequate reimbursement precluded transitioning this patient home with this form of negative pressure ventilation. We believe that negative pressure ventilation may still be a viable option for this population in the future.

Sponsored Research - None

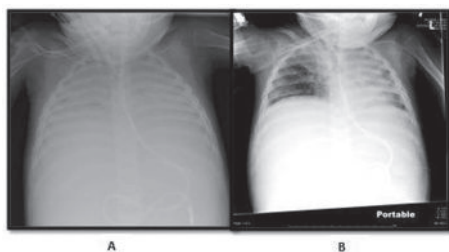
2020582

THE USE OF COMBINED NEGATIVE AND POSITIVE PRESSURE VENTILATION IN TREATING SEVERE ARDS AND AIR LEAK SYNDROME WHILE ON ECMO.

Michael Le¹, Kevin Bullock¹, Craig D. Smallwood¹, Danielle Decourcy²; ¹Respiratory Care, Boston Children's Hospital, Boston, MA; ²Medicine Critical Care, Boston Children's Hospital, Boston, MA

INTRODUCTION: Respiratory management of a patient with ARDS that has developed air leak syndrome is challenging because while positive pressure ventilation (PPV) is used to maintain lung function (FRC), it can also lead to iatrogenic lung trauma. We report a case of an individual with severe ARDS and a history of pneumomediastinum and pneumothorax in whom we were able to apply PPV and negative pressure ventilation (NPV) to increase aeration without promoting air leak. **CASE REPORT:** A 13 month old child with a recent diagnosis of acute lymphocytic leukemia (ALL) developed respiratory syncytial virus (RSV) and required venoarterial ECMO due to persistent hypoxia, hypercarbia, and air leak. After 3 weeks on ECMO, the patient continued to have complete opacification of both lung fields and persistent air leak despite total lung rest and intermittent incremental increases in positive pressures in an attempt to recruit the lungs. Continuous negative pressure (CNEP) of -25 cm H2O along with intermittent secretion clearance was added using the Hayek RTX Respirator (United Hayek) to aid in lung recruitment. Initially, the patient's VT was 3 mL and Cdyn 0.30 mL/cm H2O (see figure A). After 48 hours, aeration improved bilaterally on PC IMV: PIP 20 cm H2O, PEEP 10 cm H2O, f 14 breaths/min with CNEP -25 cm H2O (VT 20 mL; Cdyn 2.0 mL/cm H2O) with no evidence of further air leak (see figure B). After 53 days of ECMO, this patient was successfully decannulated from ECMO. **DISCUSSION:** Despite providing ECMO, total lung rest, and intermittent recruitment using positive pressure ventilation, adequate aeration could not be achieved without exacerbating air leak. CNEP, using an external noninvasive chest cuirass in conjunction with PPV, may have allowed for improved chest wall compliance as well as a more uniform distribution of ventilation. CNEP in conjunction with PPV may be considered as an adjunct recruitment modality for ECMO patients with complete bilateral opacification and persistent air leak.

Sponsored Research - None



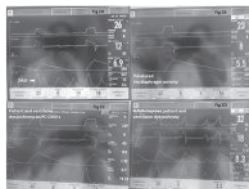
2023033

NEURALLY ADJUSTED VENTILATORY ASSIST VENTILATION (NAVA) FOR MANAGEMENT OF RESPIRATORY FAILURE IN A COPD EXACERBATION.

Justin Hoffman, Khawaja Zaki, Eduardo Mireles-Cabodevila; Cleveland Clinic Foundation, Cleveland, OH

Introduction: Mechanical ventilation (MV) has evolved since its introduction in managing patients with respiratory failure. The prognosis of critical ill patients with respiratory failure depends on their underlying etiology, and the strategy used for mechanical ventilation. Neurally adjusted ventilator assist (NAVA) is one of the newest developments in MV. It is an assisted mode of MV which uses the electrical activity of diaphragm (EAdi) to trigger the ventilator breath. This allows breath to breath assessment of ventilator assist and thus improvement of patient ventilator asynchrony. **Case Report:** 58 year old male with past medical history of hypertension, >40 pack yr former smoker and very severe COPD with FEV1 of 15%, admitted with acute hypercapnic respiratory failure at outside hospital requiring intubation. On presentation he was intubated and sedated remained desynchronized with the ventilator, afebrile, BP 134/96, Pulse 84/bpm regular. Poor air entry bilateral with wheezes but no crackles or JVD Labs were significant for Hb of 10.8, HCO 31, ABG 7.31/65/107/32/97 on 40% FiO2 on ventilator. CXR showed hyperinflation. Initial ventilator settings were PC-CMV with Inspiratory pressure (IP):15, PEEP:12, Peak pressure(Ppeak):27mmHg, mean pressure(Pmean):15mmHg, AutoPEEP 15mmHg after paralysis and static compliance was 129 lit/cm H2O. He was placed on NAVA with levels between 2-5cm H2O/µV, EAdi peak 8-18µV, PEEP +8mmHg, Ppeak 32mmHg and Pmean 13mmHg. The airway pressures didn't change significantly however; it improved patient ventilator desynchrony and decreased work of breathing. **Discussion:** Patient ventilator asynchrony is common and presents in 25% of MV patients and can lead to increased need for sedation and neuromuscular blockade, barotrauma, ventilator induced lung injury and prolong need for MV. The presence of intrinsic PEEP and dynamic hyperinflation as seen in our patients with COPD can lead to ineffective triggering. NAVA utilizes EAdi signals to determine the timing and level of ventilator assist resulting in synchrony between the ventilator flow and neural respiratory cycle. Until now there are no clinical trials suggesting its role in improving outcome. However, improving asynchrony has been shown in various physiological studies in animal and healthy individuals. NAVA is a new promising tool for clinician and researchers in the field of MV. Future trials needed to evaluate its indications and effectiveness in improving outcome.

Sponsored Research - None



Synchrony waveforms

2021247

POST-ICU MECHANICAL VENTILATION: OUTCOMES OF THE REVISED THERAPIST-IMPLEMENTED PATIENT-SPECIFIC (TIPS) WEANING PROTOCOL.

Glenn Payne¹, Douglas Vela¹, Meg Hassenpflug¹, David R. Nelson¹, Scott A. Sasse¹, Jillisa Steckart^{1,2}; ¹Barlow Respiratory Hospital and Research Center, Los Angeles, CA; ²VA-GLAHS, Los Angeles, CA

Introduction: Barlow Respiratory Hospital (BRH) is a 105-bed long-term acute care (LTAC) hospital network that serves as a regional weaning center, accepting chronically critically ill (CCI) patients transferred from the ICUs of hospitals in southern California. Patients have been weaned using the Therapist-Implemented Patient Specific (TIPS®) weaning protocol since 1998 (CHEST 2001; 119:236-242). Herein we report weaning outcomes after the implementation of our most recent revision of the protocol compared to outcomes of the previous calendar year. **Method:** An interdisciplinary task force was formed to review existing protocol and seek opportunities for improvement. Literature review was performed to update evidence base of ICU and LTAC weaning practices, stability and weaning parameters, ventilator modes, and other protocols. Input was solicited from staff pulmonologists and other key stakeholders. Protocol revisions were drafted, circulated, and discussed; expert opinion was utilized for decisions lacking a true evidence base. EHR documentation was updated to reflect protocol revisions and provide data for compliance monitoring. After training of all staff, revised protocol was applied to patients admitted from 3/3/2014 forward. Outcomes (weaned, vent-dependent, died) were scored at BRH discharge for both cohorts; weaned defined as patient being free of invasive mechanical ventilation for at least one full calendar day prior to day of discharge. **Results:** Two key protocol revisions were realized to "accelerate" weaning: 1) daily rapid shallow breathing index (RSBI) measurements to assess for earliest opportunity to advance to self-breathing trials, and 2) up to three daily reassessment opportunities to advance multiple steps in the protocol. From 3/3/2014-5/28/2014 33 CCI patients admitted for weaning reached outcome. These preliminary results are compared to 297 CCI patients treated by the same physicians and staff in 2013. **Conclusions:** These very preliminary results show a significant decrease in time to wean after implementation of revised weaning protocol incorporating additional "acceleration" steps while maintaining conservative safety and stability screens. Fewer days on mechanical ventilation may translate to less risk of ventilator-associated events/infection, enhanced rehabilitation opportunities, and shorter lengths of stay. Continued rounding, reinforcement of education, and compliance monitoring will inform these findings. **Disclosures:** None

Sponsored Research - None

2025306

A CASE STUDY: USE OF BIPHASIC CUIRASS VENTILATION UPON DIAGNOSIS OF AMYOTROPHIC LATERAL SCLEROSIS.

Frank Austan¹, John D. Domanski^{1,3}; ¹Geriatric Medicine, Kennedy Long-Term Care and Rehabilitation Facility, Sewell, NJ; ²Pulmonary, PVAMC, Philadelphia, PA; ³Sub-Acute Rehabilitation Wing, Kennedy Health Care Center, Sewell, NJ

Introduction: A 68 year old white female was admitted to a sub-acute care rehabilitation facility after undergoing spinal cervical decompression surgery. The patient achieved minimal response to rehabilitation and was admitted to a long-term care facility. **Case Summary:** The patient was evaluated by neurology for progressive upper limb and respiratory muscle weakness. The evaluation resulted in a diagnosis of amyotrophic lateral sclerosis (ALS), a terminal disorder of unknown origin that is complicated by gradual reduction in lung volumes, impaired cough, speech and respiratory failure the principal cause of death. Pulmonary consultation recommended Biphase Cuirass Ventilation™ (BCV) (Hayek Medical, London, UK), a method that uses a non-invasive cuirass (shell), connected to a module which actively controls both phases of respiration cycle. BCV is designed to increase functional residual capacity, promote airway clearance and cough assistance. A didactic and hands-on competency review was provided to the nursing staff. BCV was ordered every 6 hours for duration of 15 to 30 minutes per session as tolerated and received therapy daily for a period of 52 days. Respiratory parameters were measured daily pre and post therapy for 28 days by Pulmonary Services. Parameters were averaged and percent change documented in the medical record. **Discussion:** In this case BCV was initiated upon diagnosis of ALS improving the patient's tidal volume (363 ml Æ 34 %), vital capacity (0.950 L Æ 19 %), decrease in respiratory rate (17 BPM Æ 37%), improved comfort and tolerance between the equipment and patient interface. The nursing staff found BCV to be user-friendly and efficient in reducing the labor intensiveness of administering deep breathing exercise, chest physical therapy and cough assistance. We infer given the terminal nature of ALS and eventual respiratory failure, the early introduction of BCV may assist in establishing a Segway that "bridges" improvement in the patient's compliance and tolerance of the device. BCV also provided in this case greater comfort by not having to wear a full face BIPAP mask that prevents verbal communication as well as increasing the risk of facial tissue breakdown. Another added advantage is the delay BCV provides in the inevitable need for a tracheostomy and conventional mechanical ventilation. **Resource:** Cuirass Ventilation: A review and Update. Critical Care and Resuscitation 2004; 6: 113-122 **Sponsored Research - None**

Sponsored Research - None



Cuirass (Shell) and Power Monitor